


PRESENTING CLINICAL SIGNS

History: Grade III/VI murmur. Panting. Receiving gabapentin, phenobarbital, Keppra, galliprant, and thyrotabs.

DATE

5/11/23

ECHOCARDIOGRAPHIC FINDINGS

2D, M-mode, and Doppler study.

PERFORMED BY:

Shari Reffi, CVT

INTERPRETED BY

 Keith Blass, DVM,
 MS, DACVIM
 (Cardiology)

Left atrial size is normal. The mitral valve leaflets are mildly thickened, and a mild to moderate jet of eccentric mitral regurgitation is present. There is mild left ventricular dilation. Left ventricular systolic function is normal. The aorta and aortic valve are normal. Right atrial and right ventricular dimensions are normal. The tricuspid valve leaflets are mildly thickened, and a mild jet of tricuspid regurgitation is present. TR velocity does not suggest the presence of pulmonary hypertension. The pulmonary artery and pulmonic valve appear normal, though trace pulmonic insufficiency is present. No pericardial effusion or cardiac masses are seen.

PATIENT

Kira Shinn

 LA – 35.9 mm
 LVIDd – 35.4 mm
 LVIDs – 21.8 mm
 FS – 38.4%
 RA – 23.6 mm
 LVOT – 1.02 m/s
 RVOT – 0.70 m/s
 TR – 2.20 m/s

SPECIES

Canine

ASSESSMENT/RECOMMENDATIONS

Degenerative mitral and tricuspid valve disease

BREED

Husky

This examination demonstrates regurgitation of blood across Kira's mitral and tricuspid valves resulting from degenerative valve disease. The hemodynamic effects of each of the regurgitations appear to be mild, as Kira does not have secondary dilation of any of her cardiac chambers. As such, Kira's valvular diseases appear to be well-compensated, and it's unlikely that her panting is cardiogenic in origin.

SEX

Thoracic radiographs may be warranted to further evaluate Kira's panting.

FS

No therapy appears to be warranted at this stage of Kira's valvular diseases based on her echocardiogram.

AGE

A recheck echocardiogram is recommended in 6 months to monitor for disease progression.

12 y

WEIGHT

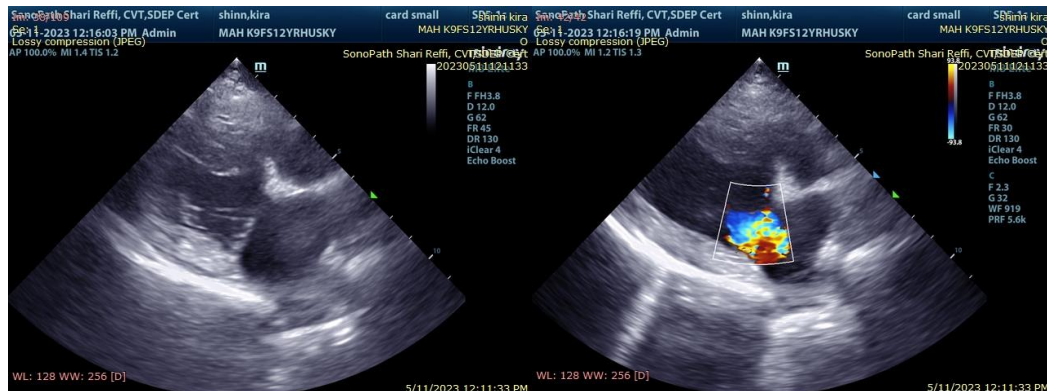
43.5 lb

HOSPITAL NAME

Milford AH

REFERRING VET

Dr. Grasso





DATE The information and recommendations provided are based on the images presented by the referring veterinarian. No evaluation can be communicated regarding pathology that was not visible in the image/video clips provided.
5/11/23

PERFORMED BY: Thank you for this referral. If the clinical or image interpretation does not parallel your findings or if I can be of any further assistance please contact me.

Shari Reffi, CVT

INTERPRETED BY Keith Blass, DVM, MS, DACVIM (Cardiology)
KeithBlass@gmail.com
631-804-5754

Keith Blass, DVM,
MS, DACVIM
(Cardiology)

PATIENT

Kira Shinn

SPECIES

Canine

BREED

Husky

SEX

FS

AGE

12 y

WEIGHT

43.5 lb

HOSPITAL NAME

Milford AH

REFERRING VET

Dr. Grasso